
INDEPENDENT MEDICO-LEGAL OPINION

MY REFERENCE: P5 (2017)

Case: Death of Ahmed Timol 27th October 1971

by Dr S R Naidoo

Independent Forensic Pathologist

DATED: 24th July 2017

MEDICO-LEGAL REPORT

[My reference: P5 (2017)]

A: CASE DETAILS

1. Death of Ahmed Essop Timol (Date of death: 27th October 1971)

B: INSTRUCTION

2. Instructions received from Webber Wentzel Attorneys, 90 Rivonia Rd, Sandton, Johannesburg, 2196: To study the medical evidence of the first inquest (1972) in the matter of the death of the deceased and provide an independent opinion on the nature, circumstances, manner and mechanism/s of the death of the deceased, and on any pertinent and related aspects thereto.

C: CONSULTANT CREDENTIALS

3. See Annexure at end of this Report.
4. It is relevant to state herewith, amongst other aspects of my professional practice, that wound identification, pathology and injury reconstruction to context are in the domain of forensic pathology and within my expertise. I am the sole author of this report and am wholly responsible for its contents.

D: SOURCES OF INFORMATION FOR OPINION

5. The original autopsy report of Dr N J Schepers (and a translation)
6. Copy of the original inquest record of 1972, from page 653 onwards: the principal sources of written information are transcripts of the oral testimonies (english text only) of Dr Schepers, Dr J Gluckman and Professor H Van Praag Koch.
7. Statements of J A Roderigues and G J Deysel.
8. Seven sepia-toned photographs of the body at the mortuary where the autopsy was done.

* NUMBERINGS BEGIN AGAIN
WITH ① HERE - REQUEST TOLERANCE.


[Ref: P5 (2017)]

E: SUMMARY OF ESSENTIAL MEDICAL FACTS FOR OPINION

1. The essential facts of the autopsy findings are depicted in the translation of the autopsy report (attached as Annexure A) at my request by a colleague, Dr K C Quarrie, specialist forensic pathologist, Durban, between the 12th and 14th July 2017. I have studied the translated version against the original and found it very acceptably done and this was amended by me to enumerate the injuries (as in its Annexure I). The injuries were subsequently drawn by myself (to the best depictions possible) onto diagrams (my attached six Annexures B to G in this report) from the descriptions in the text of the report and from observations on the photographs of the body.
2. The record of J A Roderigues regarding his version of the final moments of the deceased's life is as per his statement in Afrikaans dated 11/11/1971.
3. The description of G J Deysel in regard to the position of the body when it was found after the fall off the building is as per his statement in Afrikaans dated 16/11/1971, and is interpreted by me as follows:
 - a. The deceased fell into a garden section into some shrubbery on sandy ground below the building, not on tarmac or paving or cemented ground.
 - b. He was found lying on his stomach (face down), his face is slightly turned to the right. The head faces the building he fell from. There is a shrub on his right side roughly adjacent to his shoulders and chest. Some branches of the shrub lie under his shoulders and chest.
 - c. His right upper limb is tucked under his body, and his left upper limb slightly away from his body with the wrist turned upwards. The right lower limb is fractured/broken at mid-thigh and bowed inside (I would assume that the right knee is turned inwards to the other leg but they are apart, and the right thigh is seen as broken). The left leg is straight. Both legs are slightly apart. No shoe on right foot. (There is a shoe on the left foot).

Declarations

4. The embedded image below, drawn purely from the description by Deysel, should not be construed as the precise lie of the body when it landed upon the ground but is my own pictorial reconstruction from text only of the lie/alignment of the body when seen upon the ground after the fall:



* MAY BE IMPRECISE
FROM DEYSEL'S
DESCRIPTION
ONLY.*

F: DISCUSSION OF FINDINGS

5. The main limitations to my analysis include:
- Absence of the two independent original reports or findings by Dr Gluckman and Prof Koch;
 - Absence of what appears to be the initial 652 pages of the original court records;
 - Untranslated transcripts (Afrikaans text) of court proceedings; and
 - Comprehensiveness of the original autopsy report.

Thus, this report as an analysis of only the source materials above.

Shortcomings of the autopsy report

6. My assessment of the original autopsy report is that, despite appearing detailed, it falls short of the expected completeness and inclusiveness that should have accompanied the investigation of a death in custody, in that:

- a. there were no x-rays taken, to detect and also to characterise the types and patterns of fractures; alternatively, the fractures were not dissected into and degree of haemorrhagic vital reaction described;
 - b. the skull fractures were not drawn onto diagrams to assist in a legal process as correct visual depictions of fracture patterns;
 - c. there were no wound measurements taken, except for one surface lesion;
 - d. the macroscopic descriptions of surface wounds and internal injuries, and accompanying tissue reactions, were minimal or absent in any detail;
 - e. no toxicological analysis was conducted.
7. My impression is also that the autopsy was conducted and the report written of its findings without anticipation of the expected line of medico-legal inquiries which would include whether the deceased was alive at the time of the fall, and whether the deceased was under the influence of any drugs at the time of death.

Value of histological examination of wounds to determine their age

8. The greater portion of the available original inquest record, from page 653 onwards, concerns the oral testimony of the pathologists which delves with exceptional detail into the histological (tissue microscopy) age determination of abrasions and bruises on the body of the deceased. I have not done a complete analysis of this evidence in the transcript since I believe it will be unnecessary. To explain, it is critical to elucidate the true value of the histological examination of tissues to the context of this case, where I believe the histological examination served a good purpose but which was limited.
9. In the period in which the autopsy was done, the 1970's, the value of histology (and histochemistry) of wounds in the forensic autopsy was well-recognised, as it still is today. Certainly, the science of histological investigation of wound age determination is still excellent science and which has progressed considerably with the use of immuno-histochemistry and also other advanced techniques¹².

¹ Saukko P, Knight B. Knight's Forensic Pathology. 4th Edition 2016. Taylor and Francis Group LLC

² Dettmeyer, RB. Forensic Histopathology Fundamentals and Perspectives, 2011. Springer-Verlag Heidelberg

Conventional histological wound age determination “remains the basis of all wound age diagnostics”³.

10. However, the precise usefulness must truly be correctly appreciated for the methodology to be appropriately and fittingly applied to a particular case. Histology is correctly used in the first instance for the differentiation between ante-mortem (intravital) and post-mortem wounds. A finding that a wound is ante-mortem may usually be made on relatively confident grounds in cases where the vital reaction⁴ (evidence of early healing) is well demonstrable. Then, having determined that the wound is ante-mortem, the approximate age of the lesion is determined from the regular time-dependent occurrence of each tissue or cellular reaction, usually specified as a range in time that the wound age may be placed. It reflects the most accurate range that can be estimated from the known stage of development of the vital reaction/s examined. Because the known stages of development of vital reactions are based upon published research findings on wound age, and because these are almost always reflected as ranges in varied publications, the age estimation is never as accurate as might be desired for any particular case. There is in any estimate always some error, defined as the difference between a true value and an estimate, or approximation, of that value.

Where known ranges are used to differentiate between two or more wounds whose ages are close to each/one another in time of origin, this exercise now may become hazardous. Where the the stages of vital reaction in any two wounds are so diverse and clearly assigned to different ages (such as in the order of many days to weeks), this may be used fairly confidently to make a finding that one wound is older (or younger) than the other. Where the difference is small, in the order of hours to a few days, confidence is greatly reduced as the accumulated error of the estimations becomes exceedingly raised.

³ See Dettmeyer in 2 above, Chapter 10, page 191, 193.

⁴ Traumatization during life triggers vital reactions that do not occur in postmortem wounds” as described by Oehmichen M (*Forensic Sci Int.* 2004 Sep 10;144(2-3):221-31),

I believe therefore, in my opinion, that the efforts at the histological examination were indeed misdirected. The histological examinations served a useful purpose by establishing that the wounds 8 to 35 (enumerated wounds in my translated version of autopsy report) were ante-mortem and could not have been caused by the fall from the building. However, they cannot usefully be employed *in the context of this case* to attempt to make a distinction between wounds of a few days as was sought for at the original inquest, to any worthwhile value for a finding by a court.

What were the fall-related injuries?

11. The fall-related injuries, in my opinion, would most likely be:
- a. the bruise seen on the left forehead which could be associated with the fracture line of the forehead, and the gross skull vault fractures that extended to the base of skull and midline facial/nasal bones (see Annexure F);
 - b. the brain injury associated with the basal skull fracture above (rupture/tear of the inferior left frontal lobe near midline) (see Annexure G);
 - c. the fractured cervical spine;
 - d. (most of) the fractured ribs;
 - e. the lacerations of the lungs and contusions of the diaphragm;
 - f. the lacerations of the liver,
 - g. contusion within the heart valve ring;
 - h. torn left renal artery,
 - i. fractured right elbow;
 - j. fractured right femur

What injuries were not fall-related?

12. Except for the surface injuries numbers 1 to 7 in the autopsy report (in translated English version) and the fractured elbow and femur, and all internally-described injuries, the rest of the surface and bodily injuries (numbers 8 to 35) appear to have been ante-mortem (before death). This is deduced from the histological findings and the extensive transcribed available oral proceedings of the original inquest where all the slide sections of most of the other injuries (8 to 35) were accompanied by histological vital reaction.

13. Considering the localisation, distribution and pattern of the surface injuries 8 to 35 (as depicted upon diagrams Annexures B to E), these do not have any pattern suggestive of being sustained in the fall as described. They are multi-focal (multiple, localised and discrete/separate) and small, and present in recessed or protected areas of the body that are unusual for a fall from a great height. In any event, they are all shown to be ante-mortem by histology.
14. The wound appearances suggest that they were all caused by varied and multiple blunt-force impacts. It is not clear what degree of underlying injuries may have been associated with these, such as bruising and rib fractures. The photographs which show these surface injuries appear to suggest that the body surface bruising was forensically significant, and some accompanied by abrasions.
15. The right distal leg [calf] injury and its extensive bruising/contusions of calf muscles (Wound 19) and the dislocated left ankle and its attendant degree of bruising (Wounds 31, 32 and 35) refer. Relative to those of the other post-mortem wounds, they are by description far too extensively bruised to have been secondary to the impact of falling to the ground, especially where survival is believed to be no greater than a few minutes. These are discussed in sections dealing with separate injuries/aspects below.

Cranio-facial injury⁵

16. The skull fracture reconstruction in drawing (see Annexure F) appears to circumvent the full rigid cranial enclosure (encircles the skull vault) and runs between the forehead and superior portion of the crown and around the base. Such basal fissuring will likely have involved the full skull base and include the basal bones of the roof of the nasal cavity (sphenoid, ethmoid and nasal bones). This specific encircling fracture pattern is seen in extremely heavy and broad blunt

⁵ "Cranium" refers to the entire vault or box in which the brain is housed, thus "cranio-facial" refers to the entire skull vault and facial skeleton that sits atop the cervical (neck) spine.

force such as in falls from great heights where the skull instantaneously deforms (the “struck-hoop” phenomenon⁶) at the split instant of impact.

17. The depressed fracture at the left parietal bone – with a loose bony fragment described - refers. There is a dearth of description of this, in regard to its pattern and size, the amount of attendant scalp contusion and other effects to the brain. (The reconstructed drawing of this fracture in Annexure F is thus very approximate and imprecise). This fracture pattern, however, does not appear to be fall-related. One is led to consider as a possibility an isolated impact that is distinct from the fall. It is, however, unusual that such a fracture is not accompanied by some degree of brain surface contusion directly underneath the depressed fracture, if this were sustained prior to the fall, unless there was a failure to describe such.
18. The additional fracture that does not appear to be characteristic of a fall is the fracture of the mandible (lower jaw) at its corner/angle where it appears fragmented (broken into pieces).
19. The deep scalp bruising at the left occipital area is similarly not explained by the fall.
20. In support of the two fractures above thought not to be fall-associated is the fact that it is unlikely that several impacts were received at different and opposite positions on the cranium as a result of falling if the body was unimpeded by any other intermediary obstruction/s during the fall. The impression that I get is that, for the particular fracture pattern to the entire vault of the cranium to be sustained, is that there was a major frontal cranio-facial impact.

Brain injury

21. The injury to the brain surface is described as a global sub-arachnoid haemorrhage, especially at the inferior aspects (these may actually have been brain contusions) of the left frontal and temporal lobes with a laceration of the inferior frontal lobe, and

⁶ Saukko and Knight -see note 1 above, page 182.

internally, the petechial haemorrhages to the midbrain, pons and hypothalamus and in the white matter of the frontal lobes. These are all findings characteristic of high-velocity shearing injury, and supports my opinion that the deceased was alive at the time of the fall.

How did the body land (i.e. what part/s of body sustained impact) to ground?

22. My impressions obtained from the injuries are that the body struck the ground (primary impact) with the forehead and the area of the right shoulder/elbow/chest.
- a. The cranial vault impact likely caused the vault fracture that transmitted the force of impact through to the base of skull and to the upper facial bones (orbito-nasal and maxilla).
 - b. To account for the cervical spinal injury one possibility is that the forehead impact in this instance could have jolted the neck into possible hyperextension to fracture the 7th cervical vertebra (there is no description to suggest whether this might be from hyperextension or hyperflexion). In support of the hyperextension of the neck is the rupture of the fibres of the right sterno-mastoid muscle at insertion into right clavicle (paragraph 9 [Neck Structures] of the autopsy report).
 - c. The right shoulder and elbow impact (fracturing the elbow and transmitting the force of impact to the right-sided ribs, diaphragm and liver and left sided ribs) were also primary impact injuries.
23. The cause of the right femoral fracture as a sole injury to right lower limb is unclear but may have been a secondary impact as the body struck the ground.
24. The appearances suggest that he probably did not strike the ground with a foot or both feet as this otherwise would likely have caused massive ankle injury *plus* transmitted impulse impact up along the limb/s to the pelvis which is not recorded as fractured or dislocated. The left ankle dislocation suggests, in my opinion, that it had been sustained *before* the fall (the reasons for this are dealt with in paragraphs 31 to 35 below).

Was he alive during the fall?

25. My impression is that the deceased was alive, based upon the degree of vital reaction described (albeit scantily) in the autopsy report on the fall-related injuries:
- haemorrhage around the skull and brain injury;
 - internal petechial haemorrhages into the brain substance and the pin-point haemorrhages into the frontal lobes suggest a vital reaction to a high-velocity impact;
 - haemorrhages around the lacerations of the lungs;
 - haemorrhage around a torn left renal artery;
 - haemorrhage at the posterior mediastinum is minimal but enough to indicate survival during the fall; I suspect that an aortic tear that is characteristically seen in high falls such as this might have been missed.
26. It is, however, strange that no bleeding is reported around the liver; this might have been an error of recording by the pathologist.

Period of survival after the fall

27. From the statement by Deysel, this would appear to be no greater than a few minutes. Mr X enters the room at about 15h50, and Dr Kemp sees the body ~~taken~~ *when it lay in a passage* ^{on the} ~~up to the~~ 9th floor at 16h05. Even if the various witnesses's wristwatches or clocks were not synchronous, the survival could not have been more than several minutes.

28. From an analysis of the fall-related injuries, the amount of bleeding from the lacerations of the liver, lungs and around the brain suggest that the survival time was less than 10 minutes in my opinion (on the nature and extent of the various injuries), and probably shorter (perhaps about 5 minutes) than that.

How are the neck injuries (anterior compartment soft tissues) explained? Was the deceased strangled?

29. In paragraph 9 of the autopsy report under "Neck Structures", haemorrhages are described involving the left horn of the hyoid bone, rupture of the lateral ligament and capsule of joint between left horn and body of hyoid, haemorrhages from

corner of right mandible to clavicle and rupture of fibres of the medial right sternmastoid attachment to clavicle.

30. The impression that I have is that the descriptions of these are not those of strangulation but are those of sudden traction injuries to the superficial strap muscles and to the thyro-hyoid muscle attachments, and are suggestive of hyper-extension injury. The rupture of the sterno-mastoid muscle attachment is highly supportive of the same. This injury could have occurred on primary impact to the ground at the fall.

Left ankle dislocation – before or after fall?

31. The autopsy findings relevant to the above question included a dislocated left ankle with haemorrhage [bruising] on the lateral aspect of foot (wound 31), large contusions/bruises on the anterior part of the left lower leg near the ankle (wound 32) and a contusion of the posterior part of the left lower leg near ankle (wound 35).
32. It is known that such dislocations of the ankle, especially when accompanied by such a great amount of bruising, usually harbours a fracture (of the fibula, or talus or tibia or calcaneus, the bones making up the joint) of the joint. Such may be seen by either an x-ray or in direct dissection into the joint. It would appear that x-rays and joint dissections were not carried out by Dr Schepers at autopsy.
33. The above contusions (bruising) are far too great a vital reaction to the dislocation, considered in conjunction with the period of survival of the deceased after the fall. It is my opinion that the deceased had this injury *prior to the fall*. If the dislocation happened upon falling, the amount of reactionary haemorrhage would have been even lesser than that which I consider would have bled most prominently (viz. the liver and lungs)
34. Of incidental interest at this juncture is that on the posterior aspect of the right lower leg a large contusion/bruise (contused muscles) was also observed (wound

19). Similarly, as in the case of the left ankle, this degree of bruising appears too great a degree of vital reaction for the survival period estimated.

35. I also draw to attention that the ankle injury might account for Essop's observations above on the ambulation of the deceased. According to the statement of Salim Essop (born 21/05/1949) who was arrested together with Timol, when he saw a person on the Monday 25th October 1971, "hooded", "dragged along", "not able to walk normally", and "held up by security officers on either side of him who were holding onto the sides of the trunk", he thought that the person was Timol.

The fall: Did the deceased throw himself out of the window?

36. My impressions expressed here are as a medical practitioner in general and not as a pathologist.

37. Could the deceased have clambered up to the window ledge in the condition he was in? I believe this is immensely difficult to do with a likely left ankle fracture-dislocation and severe injury to the right calf muscles (plus the other bodily injuries which, although skin injuries, the significant somatic effects of these must be borne in mind). Generally, if he had to have tried to heave himself up to the ledge, he might have required to clamber up onto the chair or the adjacent heater panel and this would have required the necessary time interval for an injured person to execute.

38. Could the deceased have leaped up to the window sill? In addition to the lower limb injuries, the small stature of the deceased must also be considered here. Although the window ledge/sill height I estimate (from scene photographs) to be at the minimum about 900mm (just under a metre) high, it is almost improbable for a severely-injured person to be able to execute.

39. Could he have launched himself (dived through) out of the window? If this had been at all possible, and actually performed, I have great doubts whether the window aperture would have allowed such without the deceased being caught or snagged by his clothing (no clothing was described) and without his clothing being

grossly torn, and without significant and deep linear scratch or friction abrasions and/or lacerations being seen upon the body (aside from the healing abrasions and bruises that were seen).

Could the person in the room with him just before his fall not have reached him in time?

40. The height of the deceased was 1,6 metres and Sgt Rodrigues (from the images in the room taken on the same day of the death) looks to be a relatively tall person. Consideration must be given to whether he could not have simply grabbed at the deceased during the alleged attempt to get out of the window (although this is not in my scope and ambit as a pathologist to comment upon as an expert).

The cause of death

41. The death was caused by the massive head (brain) and chest injury (vital centre damage and compromised respiration). In my opinion, from the available record, the loss of blood within and outside the body was not significant to any degree.

Was it possible for the ante-mortem injuries not to have been detected by those interrogating or having him in custody?

42. I find this considerably hard to conceive, unless he was fully clothed at all times with all skin surfaces except his face, neck and hands obscured.

Other incidental observations

43. The autopsy found that the bladder contained a “large amount of urine”: he had thus not been to empty his bladder for some time, at least for several hours for the bladder to be so distended with urine. The bladder can under ordinary circumstances fill up to about 500 mls in at least 6-8 hours. In the context of this detainee a possible state of under-hydration must be considered.

44. Contusions on the top of three of the left toes: – this is highly unusual from the fall itself, and I believe this was not highlighted by the pathologists at the autopsy simply because it might have been “assumed” that these were due to the fall. Serious consideration must be given to the possibility that these were ante-mortem

injuries and the mechanisms of how these could have been caused should be considered.

Was the deceased conscious when he fell?

45. One is not able to, by any means at all, establish whether the deceased was conscious or unconscious during the fall.

H: ANNEXURES TO REPORT

46. The following Annexures are appended to this report:

- a. Annexure A: Autopsy report translated into English text
- b. Annexure B: Diagram of front of body
- c. Annexure C: Diagram of rear of body
- d. Annexure D: Diagrams of sides of body
- e. Annexure E: Diagrams of hands and wrists
- f. Annexure F: Diagrams of skull and face
- g. Annexure G: Diagrams of brain



.....Dr S R Naidoo

23rd July 2017

END OF REPORT

See overleaf for Annexure: Credentialling and Contact details of Consultant

ADDENDUM: Credentialing and Contact Details of Consultant

- i. **Full names:** Segaran Ramalu Naidoo (known as Steve), Identity number 590406 5042 08 5; 9 a complete CV may be made available if required)
- ii. **Registration:** Medical practitioner registered as a specialist forensic pathologist in the category of independent practice with the Health Professions Council of South Africa (HPCSA) and with registration number MP 0248118.
- iii. **Qualifications:** *MB ChB (Natal); D For Med (SA); MMed Forensic Pathology (Natal); MFFLM*
- iv. **Experience:** As at 2017 I have had 34 years of experience in forensic pathology, 26 years of which were as a specialist, and 18 years of which in the joint academic staff of the University of KwaZulu-Natal, and for 8 years (2003 – 2011) as Associate Professor and Head of the Department of Forensic Medicine. I was a Honorary Research Fellow at the School of Law at the same university until January 2016, Chair of the African Network (now Society) of Forensic Medicine (ASFM), member of the Forensic Advisory Board of the International Committee of the Red Cross (ICRC) and currently a member of the ministerial National Forensic Pathology Services Committee (NFPSC) of the National Department of Health, South Africa.
- v. I have at 2017 had 34 years of experience in academic and practical forensic pathology, comprising 6 years in postgraduate training and 27 years as a specialist, and of which eight were as the Chief Specialist and Professor of Forensic Medicine at the University of KwaZulu Natal in Durban. I currently am and have been in private/independent practice for my own account since March 2012.

vi. **Contact details:**

OFFICE: 25 Seaside Drive, Seaside, Tongaat Beach 4399, Durban, South Africa

BUSINESS POSTAL: PO Box 95, Desainagar 4405, Durban, South Africa

Tel: +27 32 943 1143; Mobile: +27 82 904 1143; Fax: +27 86 530 6604

E-mail: stevenaidoo11@gmail.com

ANNEXURE A
John Vosterplein: Lykskouing Nr: 305/71
Reference No. SAP.183/3991/71

AFFIDAVIT IN TERMS OF SECTION 239 (4), ACT 56 OF 1955 AS AMENDED BY
SECTION 8 OF ACT 96 OF 1965
REPORT ON A MEDICO-LEGAL POSTMORTEM EXAMINATION

To the Magistrate of **Johannesburg**

I, **Nicolaas Jacobus Schepers**, state under oath that:

That at Johannesburg, on the **29th day of October 1971** at **07h30**, employing my skill in Anatomy, Pathology, Medicine and Clinical Toxicology,

I examined the body of an: **Adult Indian Male**

This body was identified to me by: **Sergeant Fourie of the Medico-legal Mortuary,**

as being that of an: **[PM 3991/71]**

whose reputed age was: **30 years**

that the deceased was found dead:

- a) as informed on: **27th October 1971** at: (the time of death was not recorded)
- b) **2 days** prior to my examination.

THE CHIEF POSTMORTEM FINDINGS MADE BY ME ON THIS BODY WERE:

1. See the list of observations on pages I, II and III

As a result of my observations, I concluded that the cause/causes of death was/were:

Multiple injuries

Dated in **Johannesburg** on the **4th day of November 1971.**

Signature _____ Qualifications: **MMed (Med Forens) DOH.**

Position: **Senior State Pathologist**

18. **INTESTINES AND MESENTERY:** See Annexure III
19. **LIVER, GALLBLADDER AND BILIARY PASSAGES:** See Annexure III
20. **PANCREAS:** The pancreas was soft in consistency and almost completely autolytic and there is haemorrhage at the inferior edge.
21. **SPLEEN: Weight 210g:** The spleen appeared enlarged and ischemic.
22. **ADRENALS:** Both adrenal glands appeared ischemic.
23. **KIDNEYS AND URETERS: Right weight: 40g Left weight: 35g:** Both kidneys were of normal size and the cut surface was ischemic. The capsular surfaces were smooth. The cortex-medulla architecture was normal. The pelvis and ureters were unremarkable.
24. **URINARY BLADDER AND URETHRA:** The bladder is dilated and contains a large amount of urine. When opened the bladder measured approximately 15cm crosswise.
25. **PELVIC WALLS:** There was haemorrhage on the lateral side of the wall of the left side of the pelvis.
26. **GENITAL ORGANS:** Unremarkable.

SPINE

27. **SPINAL COLUMN:** there is a fracture of the body of the 7th cervical vertebra.
28. **SPINAL CORD:** Not exposed.
29. **OTHER OBSERVATIONS:** None
A , B, C, D, E, F, G, H, ,I, K, L, M, N, P and Q tissue for histology taken from the injuries just left of the letters as indicated on the photographs.

SPECIMENS RETAINED:

	Nature of Specimen	Investigation	Disposal
1.	Brain, lungs, liver, spleen, heart, pancreas, kidneys, adrenal glands	<i>Histology</i>	Dr NJ Schepers
<p>“O” photograph of the left side of the chest and the specimen is taken of the left side of the chest and placed in a bottle marked as “O”.</p> <p>“O1” specimen of tissue just left of the letter “O1” on the photograph (NB: when photograph “ O1” was taken, the yellow card with the mortuary body number that was placed over the area where the specimen “ O” was taken.</p>			

Annexure I

- 4. EXTERNAL APPEARANCE OF BODY AND CONDITION OF LIMBS:**
1. There is a fracture of the right elbow.
 2. There is a fracture of the mid-shaft of the right femur.
 3. Two large contusions/bruises are noted to the right forehead
 - a. One is just above the right eyebrow and
 - b. The other is 5cm above the right eyebrow
 4. The upper and lower lids of the right eye appear bloodshot (congested).
 5. There is a small fresh contusion/bruise at the outer (lateral) point of the upper eyelid of the left eye.
 6. In the middle of the forehead and just to the right of the midline there are a couple of scratch marks (approximately 1mm wide and 5mm long).
 7. On the right side of the neck there are couple of scratch marks as well as a couple of contusions/ bruises.
 8. On the anterior and superior aspects of the right shoulder there are a couple of abrasions and a couple of contusions/ bruises.
 9. Overlying the middle third of the right clavicle there is a small abrasion which is encrusted.
 10. A couple of contusions/bruises are noted to both infra-clavicular areas.
 11. There are a couple of contusions/bruises noted to the anterior part of the right upper arm.
 12. On the lateral aspect of the right elbow and the right forearm, near the elbow, there is a large contusion/bruise as well as an elongated abrasion.
 13. A couple of abrasions and contusions/bruises are noted to the posterior aspect

of the right forearm.

14. A couple of contusions/bruises are present on the right side of the chest.
15. There is a contusion/bruise just above (superior) the right iliac crest.
16. On the lateral aspect of the right iliac bone there are multiple, rounded contusions/bruises.
17. On the lateral aspect of the right thigh there are two large contusions/bruises.
18. On the medial aspect and joint of the right knee there is a large contusion/bruise.
19. On the posterior aspect of the right lower leg there is a large contusion/ bruise. (The muscles of the calf are contused).
20. On the right shoulder blade (scapula) there is an abrasion which is encrusted.
21. On the right lumbar region of the back there are a couple of abrasions that are irregular.
22. Fresh abrasion and contusion/bruising of the mucosa of the left half of the upper lip are present.
23. A contusion/bruise of the mucosa of the midline of the upper lip is noted.
24. On the left side of the neck an approximately 3cm below the earlobe there is a small abrasion which is encrusted.
25. Three (3) cm above the middle of the left clavicle a contusion is noted.
26. At the tip of the left shoulder there is a contusion/bruise.
27. On the anterior-lateral aspect of the left upper arm and the left side of the

chest there are multiple contusions/bruises.

28. Across the left forearm there is an abrasion measuring 2 x 4mm and is encrusted.
29. There is a contusion on the anterior aspect of the left carpal joint (wrist) and on the dorsum of the left hand, opposite the index finger and on the posterior aspect of the left index finger.
30. There is a contusion of the left flank.
31. The left ankle is dislocated and there is a hypodermal haemorrhage discernible on the lateral aspect of the left foot.
32. Large contusions/bruises are seen on the anterior part of the left lower leg near the ankle and on the anterior part of the left ankle.
33. Contusions/bruises are noted seen on the dorsum of the 2nd, 3rd and 4th toes of the left foot.
34. On the left posterior aspect of the chest, near the lower tip of the scapula, there is a 5cm in diameter contusion/bruise and other contusions are also noted to on the left posterior aspect of the chest.
35. There is a contusion on the left buttock posterior to the left thigh the posterior part of the left lower leg (ankle) near the joint.

Annexure II

HEAD AND NECK

5. **SKULL:** There is deep scalp bruising on both sides of the forehead and to a minor extent on the middle aspect of the forehead. There is deep scalp bruising of the left occipital area. There is a fracture of the base of the skull and a (*?the*) fracture extends posteriorly through the left orbital plate through the ethmoid bone and sella turcica and then swings to the rights and passes just anterior to the pars petrosa. There is a crack fracture hat extends upwards through the left frontal bone to the left parietal bone and terminates in the midline. There is a crack fracture that extends through the right anterior fossa, anterior to the right lesser wing of sphenoidal bone and then swings upwards through the right frontal bone and the right parietal bone and terminates in the midline without crossing the aforementioned crack fracture. There is a depressed fracture of the left parietal bone (a small loose fragment of the left parietal bone is present).

6. **INTRACRANIAL CONTENTS:** A global subarachnoid haemorrhage of the brain is noted, especially to the inferior aspects of the left frontal and temporal lobes. There is a rupture (tear) of the inferior aspect of the left frontal lobe near the midline and small fragments of bone on noted therein. There are petechial haemorrhages noted in the midbrain, pons and hypothalamus. There is blood in the 4th ventricle of the brain. Small pin-point haemorrhages are noted throughout the brain, especially in the white matter of the frontal lobes. On cut section the brain is very ischemic. The small veins of the brain are dilated and contain small thrombi.

7. **ORBITAL, NASAL AND AURAL CAVITIES:** There is a fracture of the nasal bone. Then there is a fracture of the left inferior orbital ramus where it inserts onto the nasal. There is a fracture of the inferior orbital ramus of the right side where it inserts onto the nasal bone.

8. **MOUTH, TONGUE AND PHARYNX:** There is a fracture of the right upper jaw (maxillae) between the upper lateral incisor and the canine. There is a fracture of the left upper jaw (maxillae) posterior to the upper left wisdom tooth. There is a fracture of the left lower jaw (mandible) at the corner/angle of the jaw (the left mandible is broken into pieces where the fracture is).

9. **NECK STRUCTURES:** There is haemorrhage into the tissues of the neck in the area of the left horn of the hyoid bone. There is a rupture of the lateral ligament and capsule of the joint between the left horn of the hyoid bone and the body of the hyoid bone. The thyrohyoid bone is not broken. There is haemorrhage in the underlying tissues of the right side of the neck, from the corner of the right mandible to the clavicle. There is rupture of the fibres/tissue of the right sternomastoid muscle at the insertion of the medial aspect with the right clavicle.

Annexure III

CHEST

10. **THORACIC CAGE AND DIAPHRAGM:** The left first rib is fractured laterally and the left 3-6th ribs are broken posteriorly and paravertebrally. The right 1st to 7th ribs are fractured laterally and posteriorly and the right 8th to 11th ribs are fractured paravertebrally. There are contusions of the left dome of the diaphragm and the right dome of the diaphragm where it is attached to the ribs.
11. **MEDIASTINUM AND OESOPHAGUS:** There is haemorrhage of the tissues of the posterior mediastinum opposite the bifurcation of the bronchi.
12. **TRACHEA AND BRONCHI:** The trachea and bronchi contain blood and mucus
13. **PLEURAE AND LUNGS:** The right pleural cavity contained 230ml of blood and the left contained 130ml. There is a rupture of the lateral aspect of the lower lobe of the right lung, 8cm long. There are multiple ruptures of the base of the right lung, the largest is 6cm long. Contusions of both lungs were seen over the paravertebral areas and the bases and dorso-lateral aspects, mainly the upper halves and especially the apices are severely contused. Both lungs show internal contusions of the posterior aspects of the upper lobes. The right lung weighs 400g and the left lung 350g. On cut section both lungs are ischemic, except for the ruptured (lacerated) areas. Aspirated blood can be seen in both lungs. There is still very little oedema of the lung.
14. **HEART AND PERICARDIUM:** The heart is not enlarged. Sub-epicardial petechial hemorrhages are noted especially over the base of the heart. There are contusions of the anterior cusp of the mitral valve. There is a practically no blood in the heart. The coronary arteries were completely normal. The heart weighed 250g.
15. **LARGE BLOOD VESSELS:** There is mild atheroma of the abdominal aorta. The left renal artery is torn and there is haemorrhage in the surrounding tissue.

ABDOMEN

16. **PERITONEAL CAVITY:** No abnormality is noted.
17. **STOMACH AND CONTENTS:** The stomach contains food - potatoes can be recognised.
18. **INTESTINES AND MESENTERY:** No injury or abnormality of the bowel or mesentery is observed.
19. **LIVER, GALLBLADDER AND BILIARY PASSAGES:** The liver is ischemic and weighs 1150 and shows trans-capsular ruptures of the inferior aspect of the right lobe and the anterior aspect of the right lobe and an internal rupture of the right lobe. The gall bladder and bile fluid are unremarkable.

HISTOLOGY NUMBER: K. 23077/71

ANNEXURE TO PM REPORT PM 3991/71

Lungs: Most of the lungs sections are relatively ischemic. In other areas there are abundant amounts of blood noted within the alveoli. There is mild pulmonary oedema present but no areas of bronchopneumonia are noted.

Brain: A subarachnoid haemorrhage is noted to the surface of the brain. In this section the brain appears relatively ischemic. Clotted blood is noted within the capillaries of the brain.

Heart: Apart from the trauma of the heart muscle blood vessels there is no significant histological changes noted. The coronary arteries are still healthy. The myocardium is relatively ischemic.

Adrenals: There is haemorrhage all around the adrenal glands. No other significant pathology is noted.

Kidneys: The kidneys are autolytic and relatively ischemic. No other significant pathology is noted.

Spleen: The spleen is relatively ischemic.

Pancreas: The pancreas is autolytic and there is blood on the side of the pancreas.

SKIN SECTIONS:

A. This section is from non-Caucasian skin. On the skin there is a scab formation with a neutrophil leukocyte infiltration noted atop. Most of the neutrophilic leukocytes have pyknotic ?(word obscured) . Beneath this scab there is an epithelial base with variable cell layers and the most superficial layer is a granular layer where keratin is formed. A thin layer of keratin is already visible. This thin layer of epithelium between the scab and the underlying collagen tissue does not show any rete ridges. Underlying this thin layer of epithelium there is fresh haemorrhage.

The collagen tissue of the dermis is distorted and in the subcutaneous fat there is haemorrhage of the tissue that stretches wider than the overlying scab.

Conclusion: The tissue demonstrates a scab which is 5 to 6 days old on the skin with a fresh contusion of the skin and underlying subcutaneous tissue.

B. This is a section from non- Caucasian skin with fresh contusion of the skin and underlying tissues.

C. This is a section from non- Caucasian skin with fresh contusion of the skin and underlying tissues.

- D. This is a section from non- Caucasian skin with a scab present. The underlying epithelium is various cell layers thick and shows early keratin formation. The scab is 5 to 6 days old. There is also fresh contusion of the skin and underlying tissues.
- E. This is a section from non- Caucasian skin. There is distortion of the collagen tissue of the dermis and there is haemorrhage in the dermis and beneath the epidermis.
- F. This is a section from non- Caucasian skin that on one end has a scab present that is 5 to 6 days old. In addition, there is a fresh contusion of the skin and underlying tissues.
- G. This is also a section from non- Caucasian skin and there is a fresh contusion of the skin and underlying tissues.
- H. This is a section from non- Caucasian skin with a severe contusion of the skin and underlying tissues.
- I. This is a section from non- Caucasian skin. There is a fresh contusion of the skin and underlying tissues with in-driven foreign material present.
- J. [Omitted? - ? typographical error]
- K. This is a section from non- Caucasian skin with a fresh and severe contusion of the skin and underlying tissues.
- L. **Two Fragments:** Two fragments of tissue marked "L" if from the lip. There is no keratin layer on the epithelium and the one section shows mucus glands in the sub-epithelial area. There is a fresh contusion of the sub-epithelial tissues in every section.
- M. This is a section from non- Caucasian skin and it shows a fresh contusion of the skin and underlying tissues.
- N. This is a section from non- Caucasian skin. On lower magnification there is a scab and on higher magnification part of the scab shows a neutrophilic leukocyte infiltrate. Between the scab and the collagen of the dermis an epithelial layer has started to form. This epithelial layer grew from opposite ends and the two edges of the epithelium are now apposing is each other. At the points of apposition the epithelium is two cell layers thick but at the more lateral edges there are more cell layers. In the subcutaneous tissue there is a fibroblast activity and a very mild perivascular infiltration of mainly lymphocytic cells present.
Conclusion: This lesion is between 4 to 6 days old.
- O. This is a section from non- Caucasian skin and shows granulation tissue formation in the subcutaneous tissues. Fibroblastic and histiocytic activity is seen and there is new capillary vessel formation noted. There is a mild peri-vascular infiltrate of lymphocytes

and isolated leukocytes noted. There are also remnants of old red blood cells (erythrocytes) in the underlying tissues as well as moderately fresh red blood cells. An iron stain of this section shows hemosiderin pigment in the macrophages.

Conclusion: This lesion is at least 5 to 6 days old.

- O1 This is a section from non- Caucasian skin with a fresh underlying contusion.
- P. This is a section from non- Caucasian skin with a fresh contusion of the skin and underlying tissues.
- Q. **Two Fragments:** The one fragment from non- Caucasian skin shows traumatic injury of the epithelium with a fresh contusion of the skin and the underlying tissues. The other fragment, also from non-Caucasian skin, shows a fresh contusion of the skin and underlying tissues.
- R. This section is from a decalcified joint between the greater horn and body of the hypoid bone. There is a rupture of the periosteum on the lateral aspect of the joint and the rupture involves the cartilage between the body of the hyoid bone and the left greater horn of the hyoid bone. There is no histological evidence that can indicate that the rupture/disruption is NOT fresh.
- S. There is no damage to the walls of this artery (right carotid artery) observed.
- T. The left carotid artery: There is an area of distortion and rupture of the elastic fibres of the wall of the artery noted. This is also a fresh injury.

Signed: _____ MMed (Med. Forens.) DOH
NJ Schepers
Senior State Pathologist, Johannesburg.

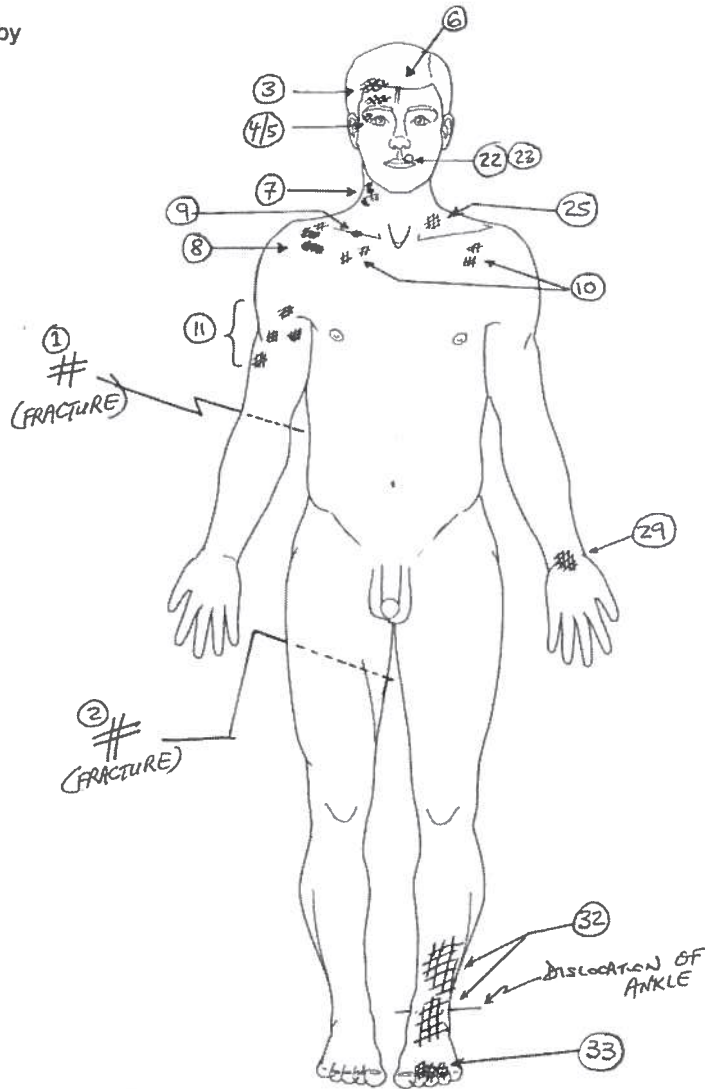
Re: Ahmed Essop Timol (DOD: 27/10/1971)

Annexure B (Dr SR Naidoo July 2017)

[Signature]

B

Examination of
on
by

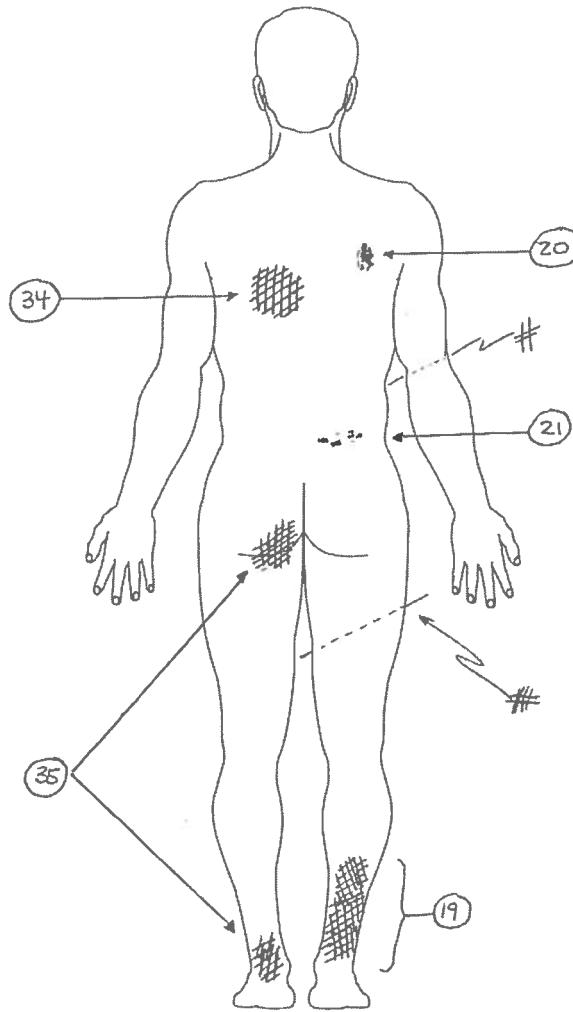


(C)

Re: Ahmed Essop Timol (DOD: 27/10/1971)

Annexure C (Dr SR Naidoo July 2017)

Examination of
on
By

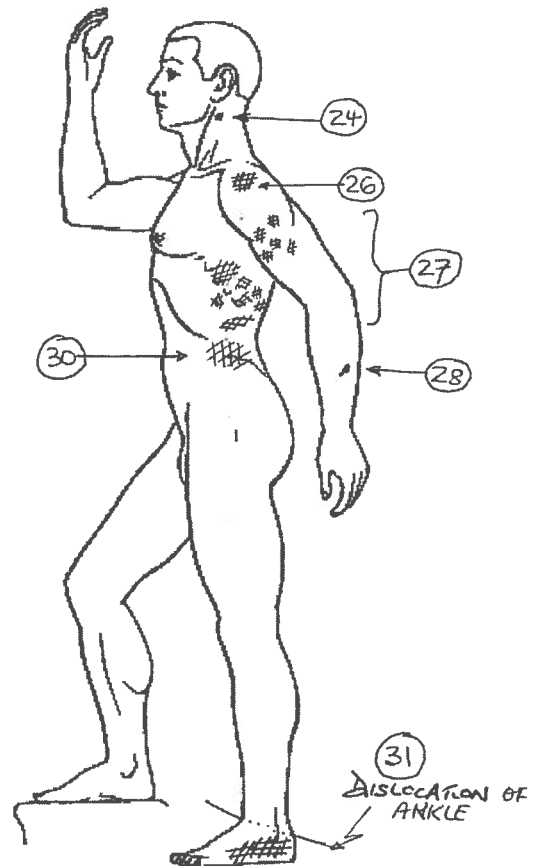
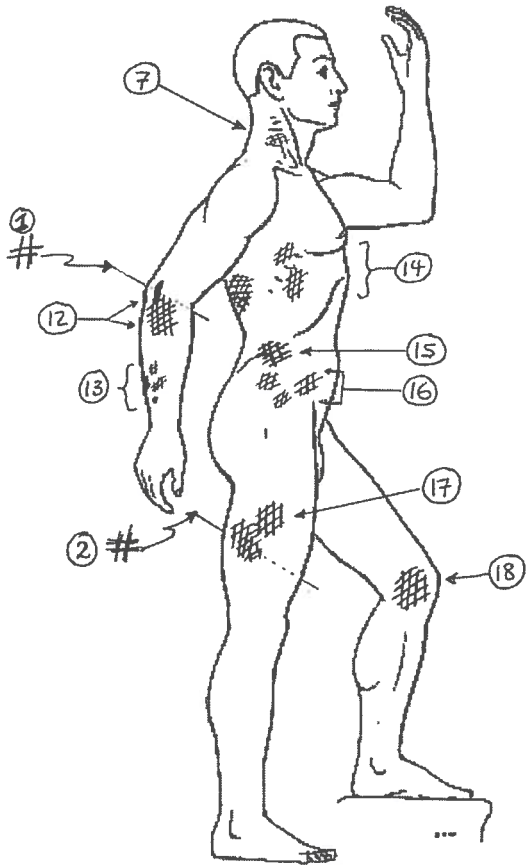


negative

Re: Ahmed Essop Timol (DOD: 27/10/1971)

Annexure D (Dr SR Naidoo July 2017)

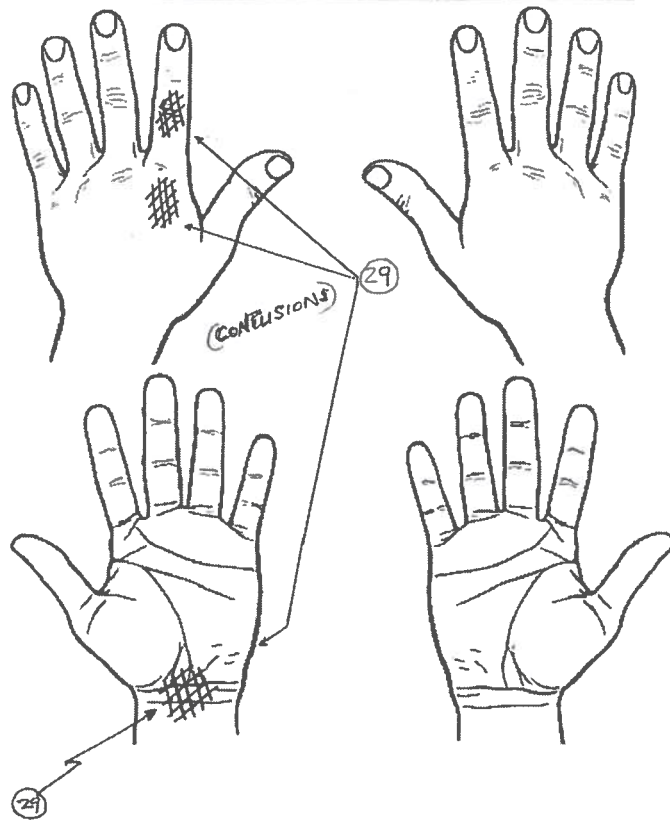
D



Re: Ahmed Essop Timol (DOD: 27/10/1971)

Annexure E (Dr SR Naidoo July 2017)

(E)

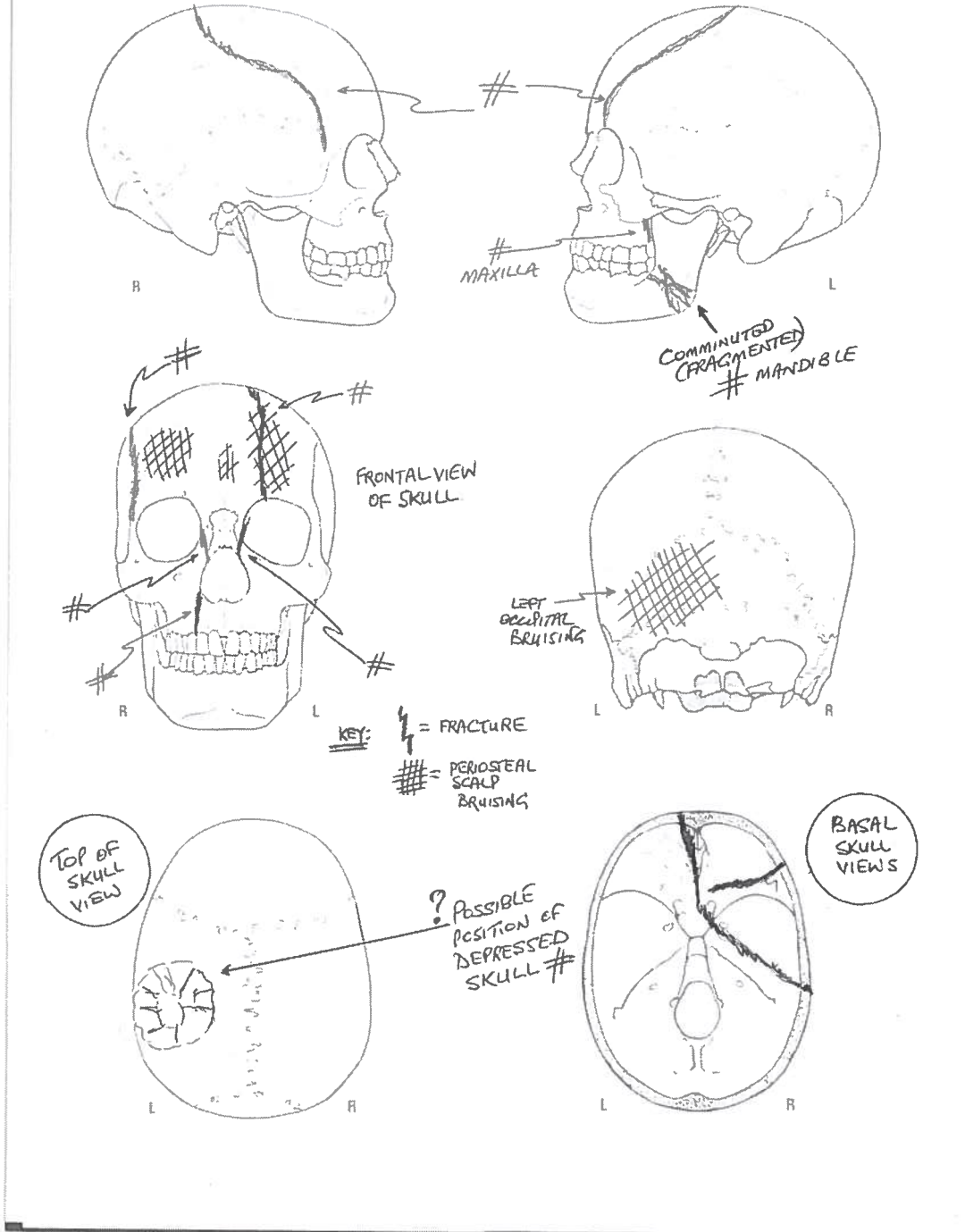


Re: Ahmed Essop Timol (DOD: 27/10/1971)

Annexure F (Dr SR Naidoo July 2017)

SR Naidoo
MEDICAL

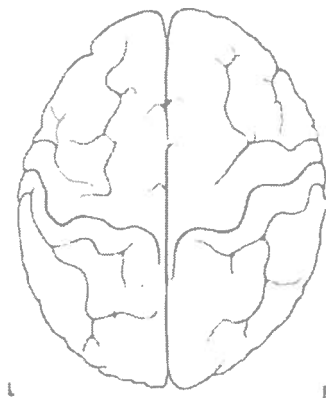
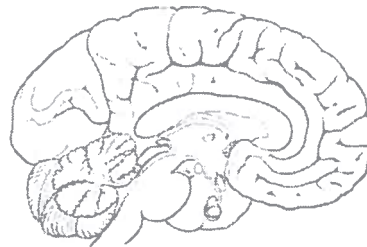
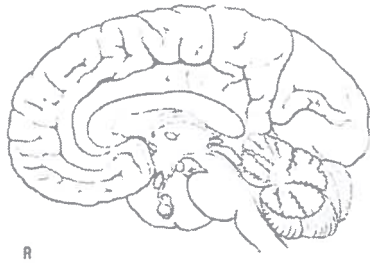
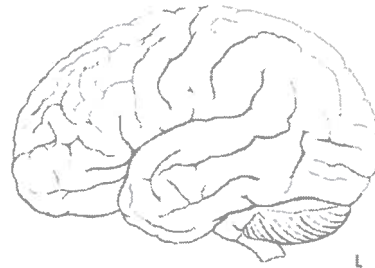
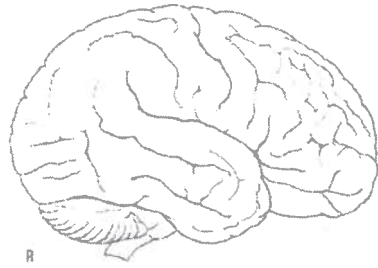
F



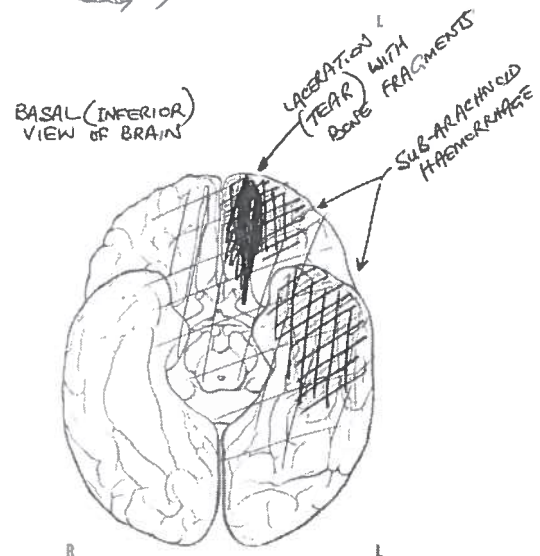
Re: Ahmed Essop Timol (DOD: 27/10/1971)

Annexure G (Dr SR Naidoo July 2017)

Bylae
Annexure



R



R

L

1: 0, 47